




INCESSANT VENTRICULAR TACHYCARDIA FOLLOWING PERMANENT HIS BUNDLE PACING



Dr. Kotti MD., DM
Consultant Electrophysiologist
Arrhythmia Heart Failure Academy
The Madras Medical Mission



Permanent His bundle Pacing

The issues related with acute performance of the pacing leads are being recognized.

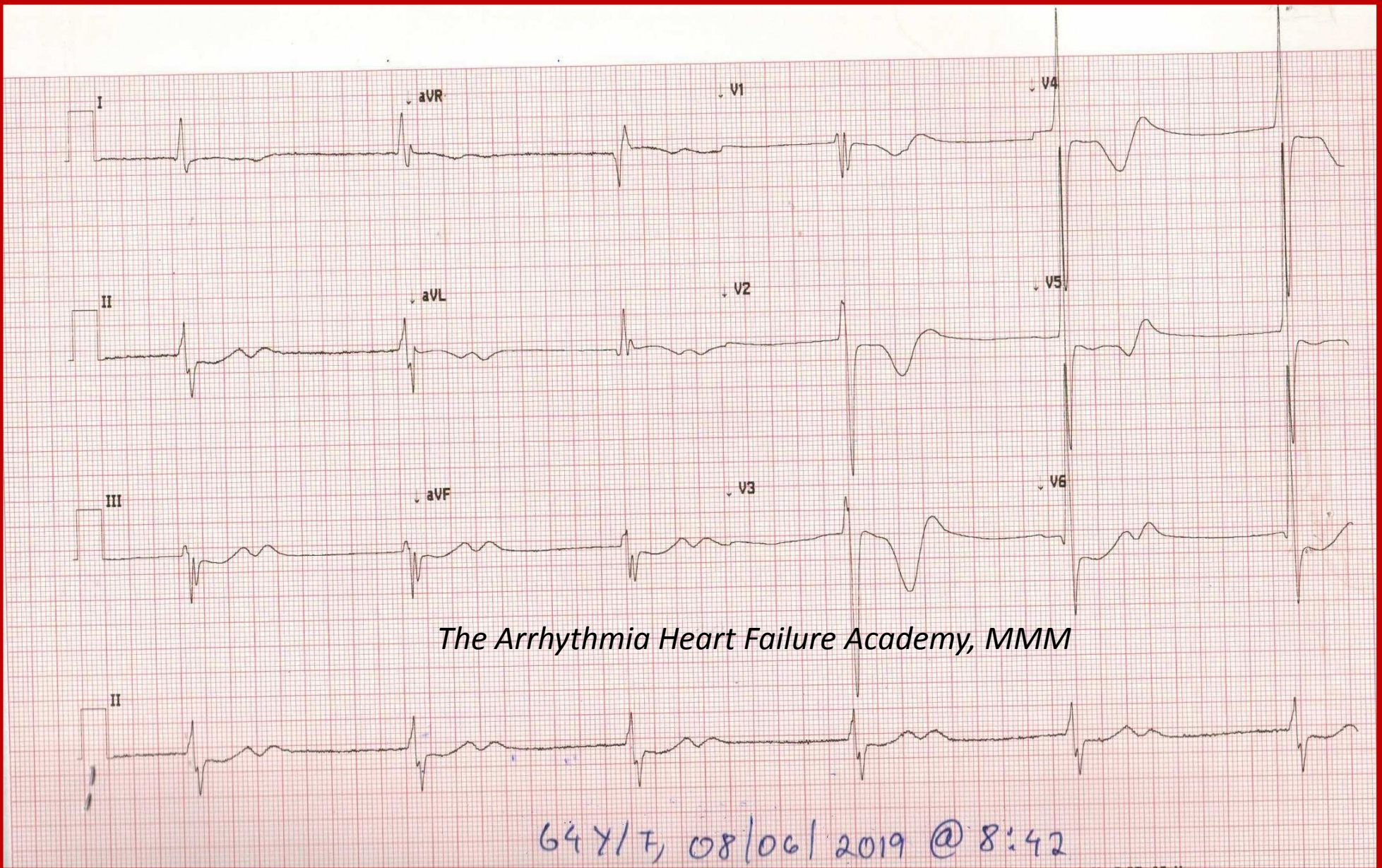
Occurrence of sustained ventricular tachycardia presumably due to myocardial and conduction tissue injury caused by active fixation lead at the His bundle has not been reported so far

A 65- year- old female, rheumatic heart disease, mitral valve replacement (22mm Omnicarbon™ mechanical mitral prosthesis, 17 years back)

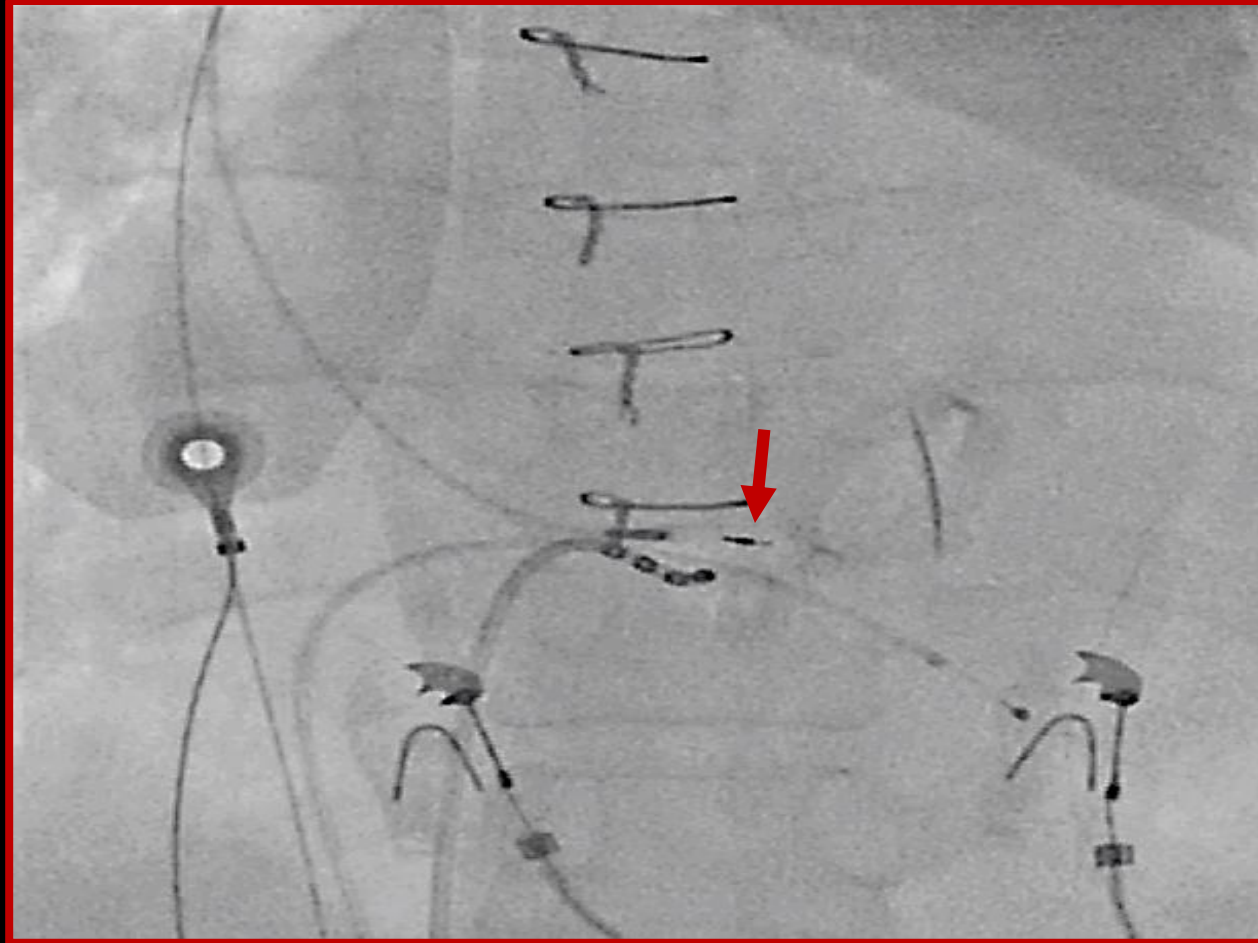Normally functioning prosthetic valve, moderate aortic regurgitation and severe LV dysfunction (EF 30%, LVID(d) 65mm)

Known to have sick sinus disease with prolonged PR interval
Nonspecific intraventricular conduction delay. Presented with syncope

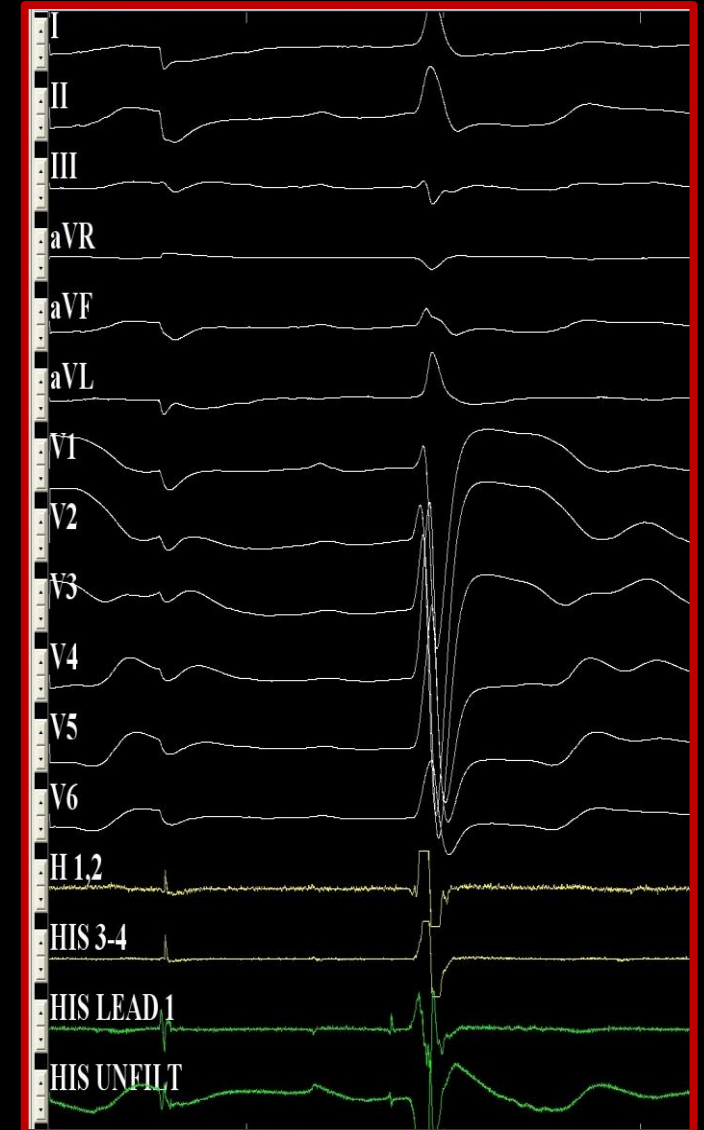ECG



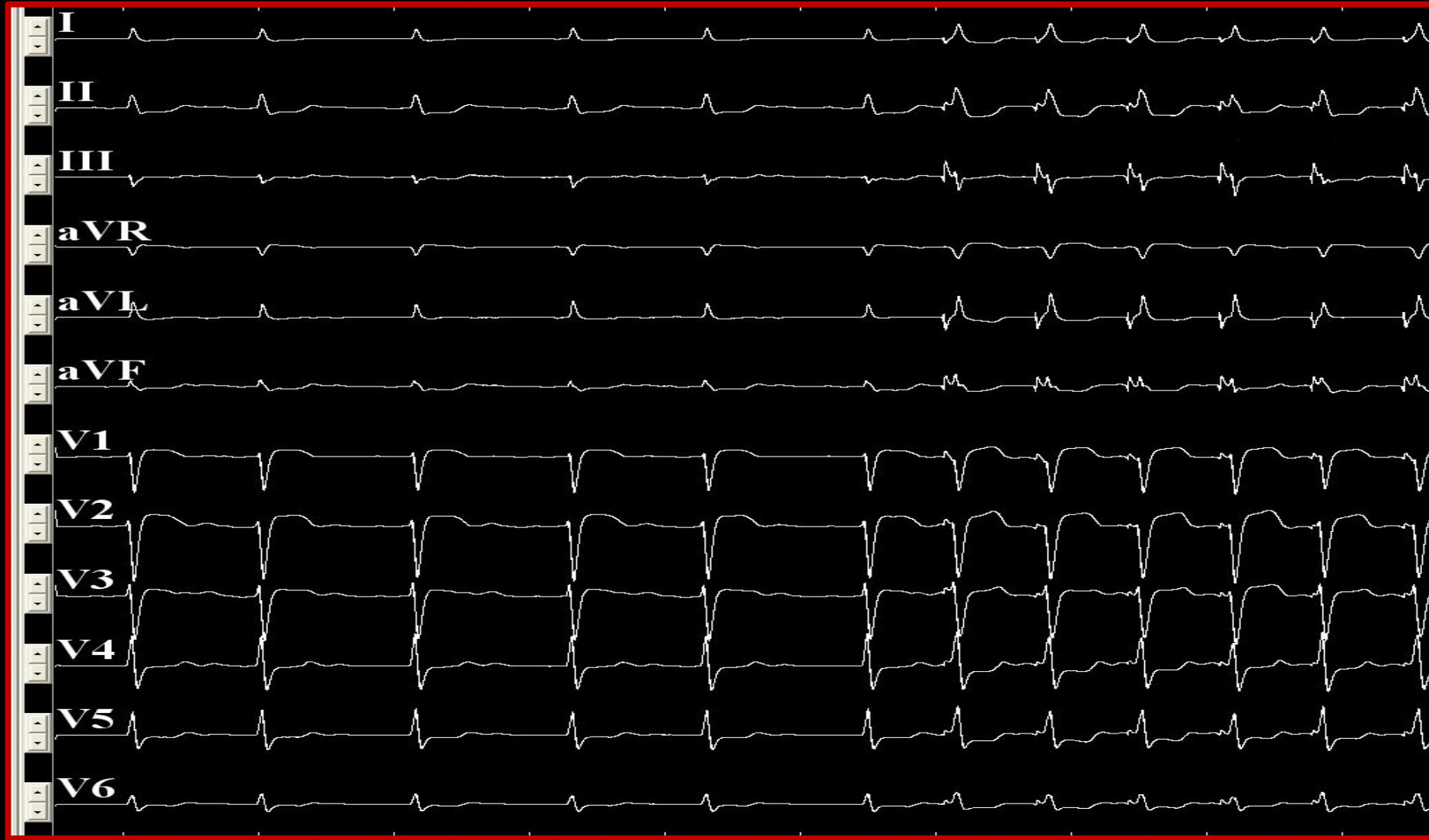Site (arrow) where the His bundle lead
(Medtronic SelectSecure™ 3830) recorded His potential



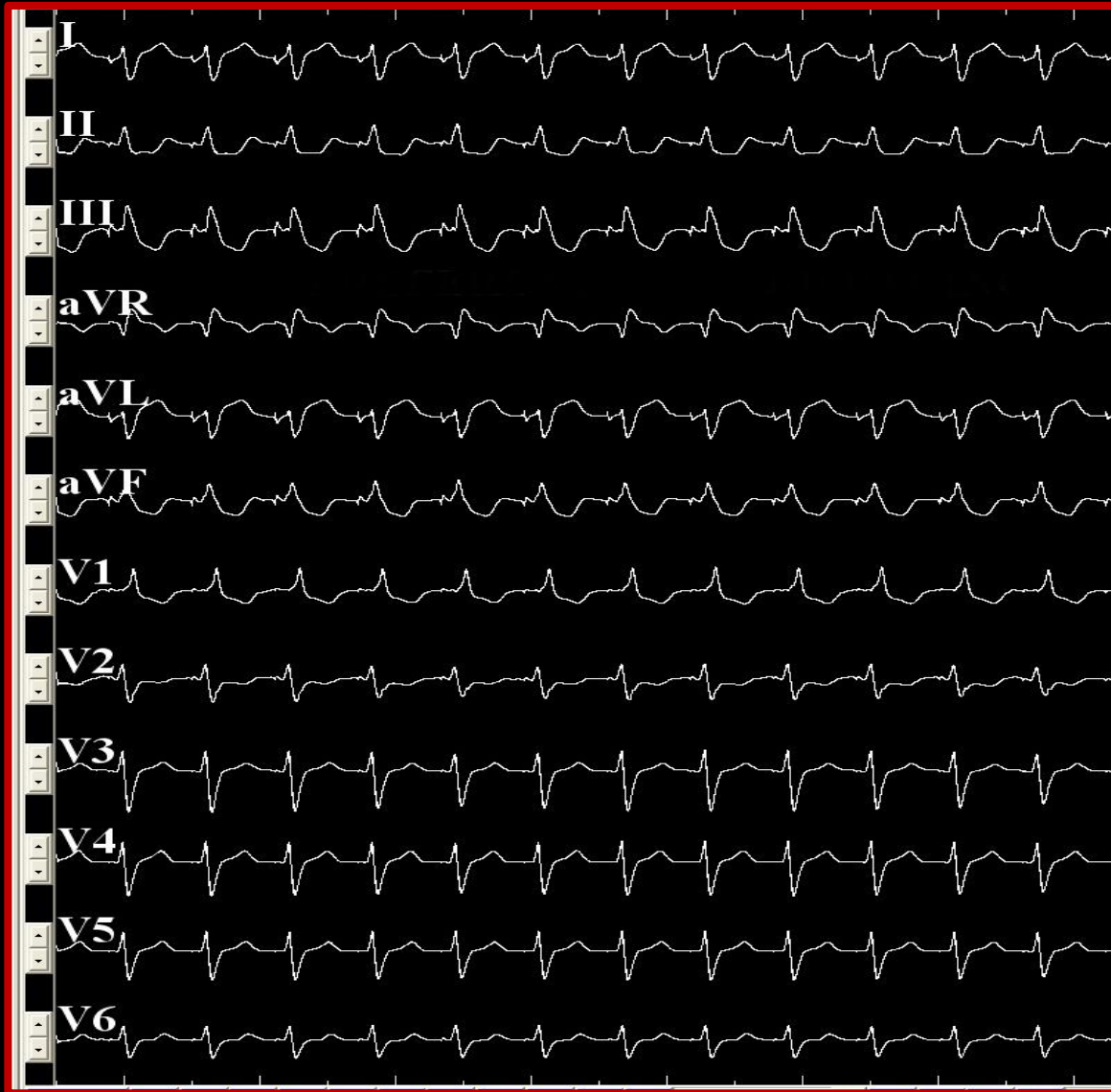His potential recorded by His bundle lead
(Medtronic SelectSecure™ 3830)



unipolar pacing (2.0V @1ms threshold) resulted in non-selective HBP with QRS duration of 20ms more than the native QRS



Paced morphology



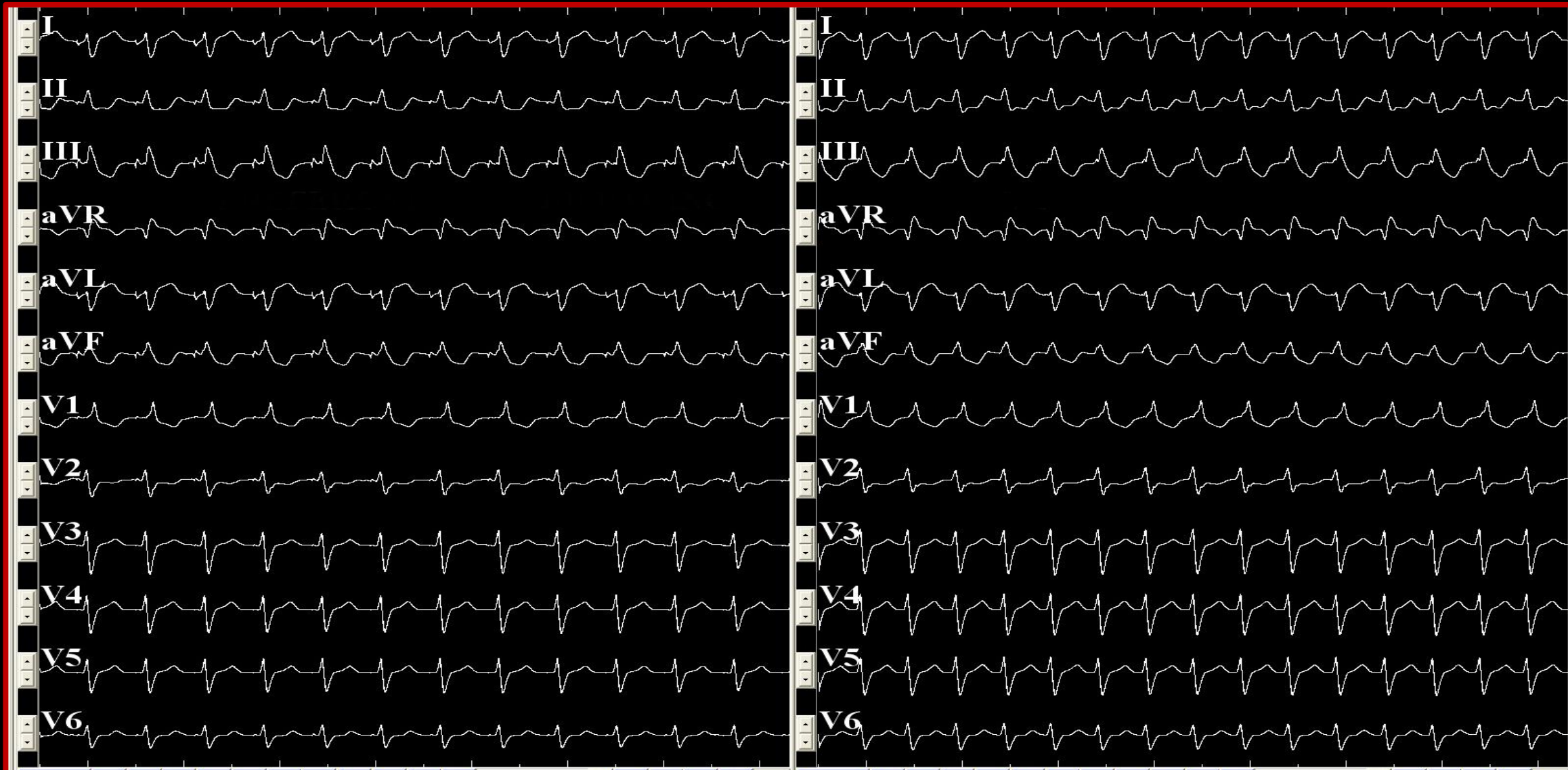
Post screwing (3 turns) bipolar HBP resulted in non-selective HBP with further QRS widening and change in morphology (1.5V @1ms threshold).

To achieve narrower paced QRS morphology it was decided to pace at a different site.

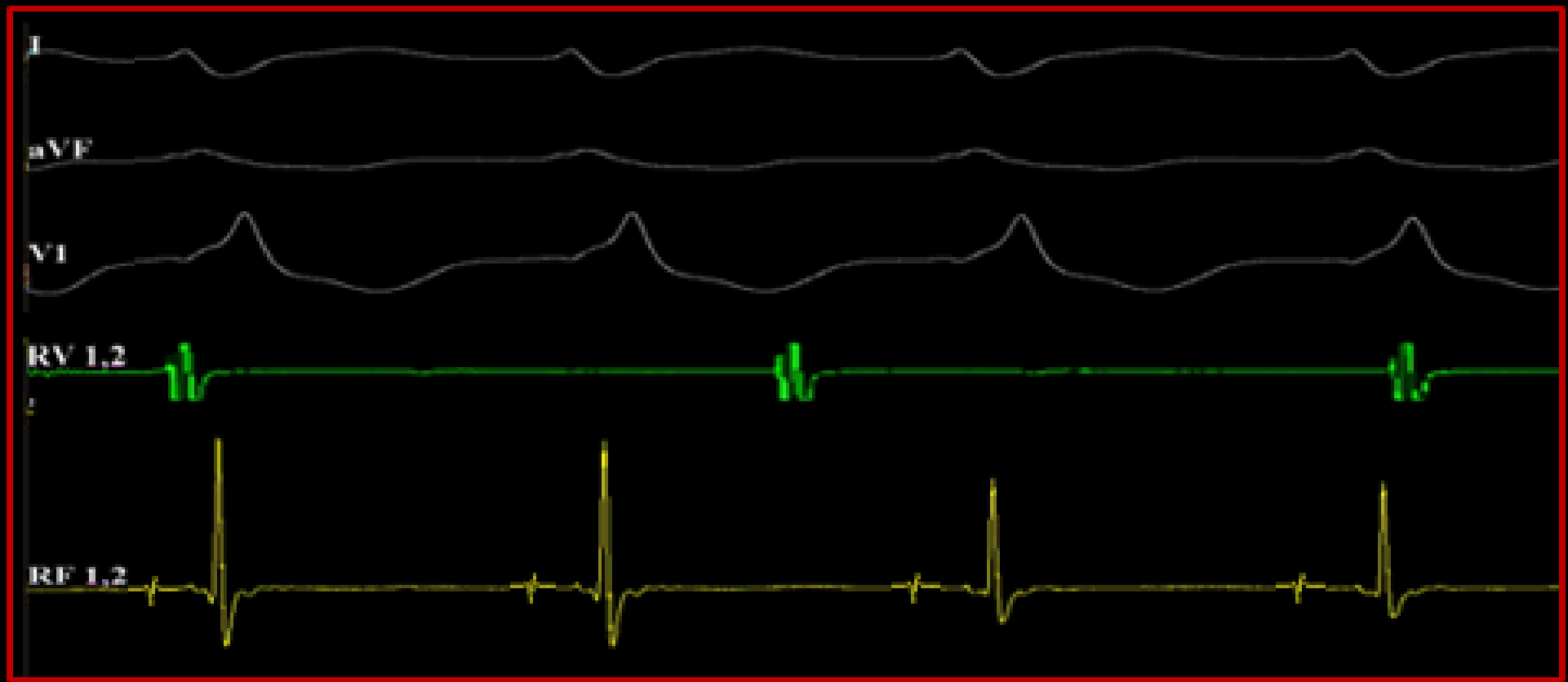
However after unscrewing patient developed hemodynamically compromised wide QRS tachycardia which is exactly similar to paced QRS morphology

Paced morphology

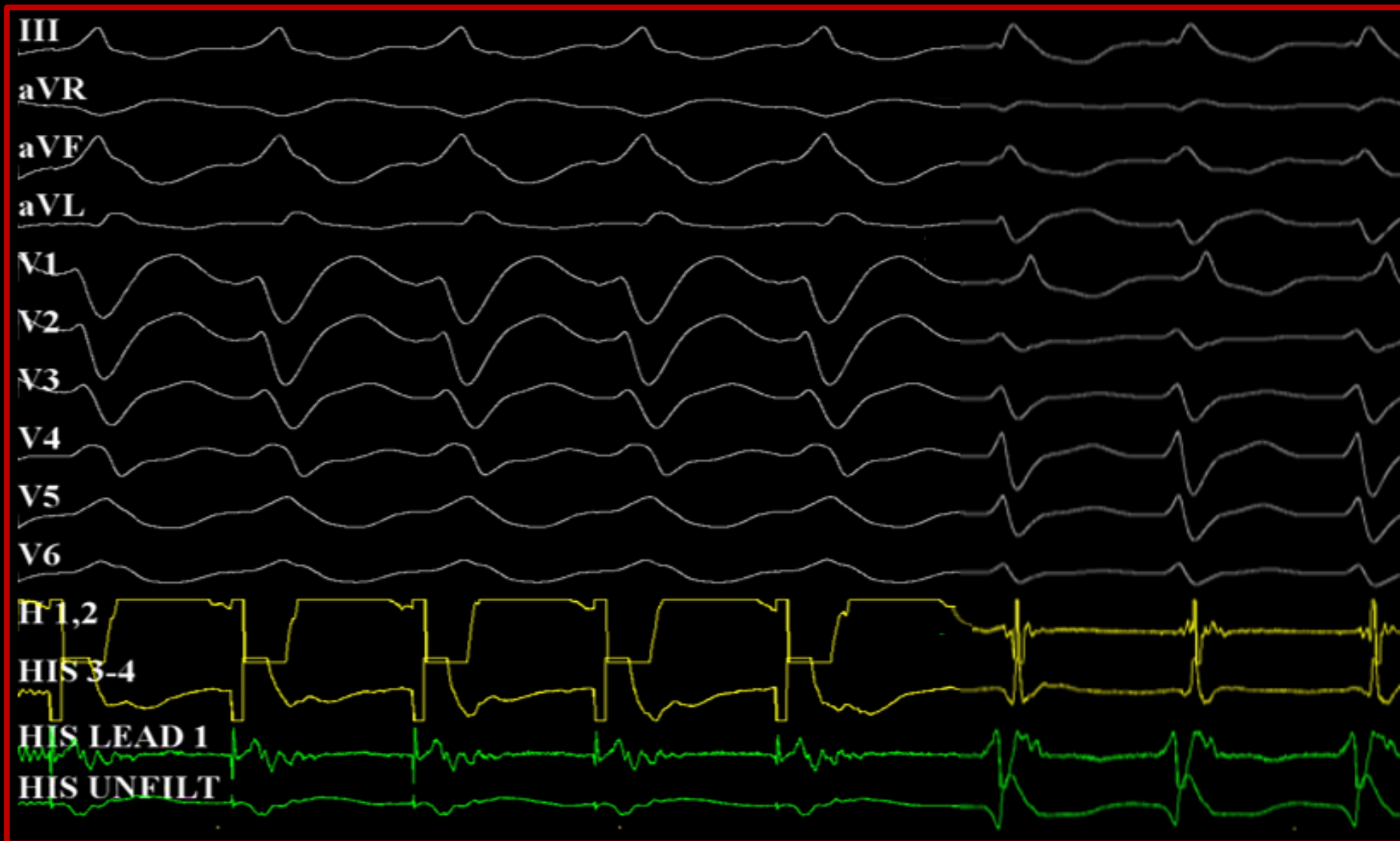
Tachycardia



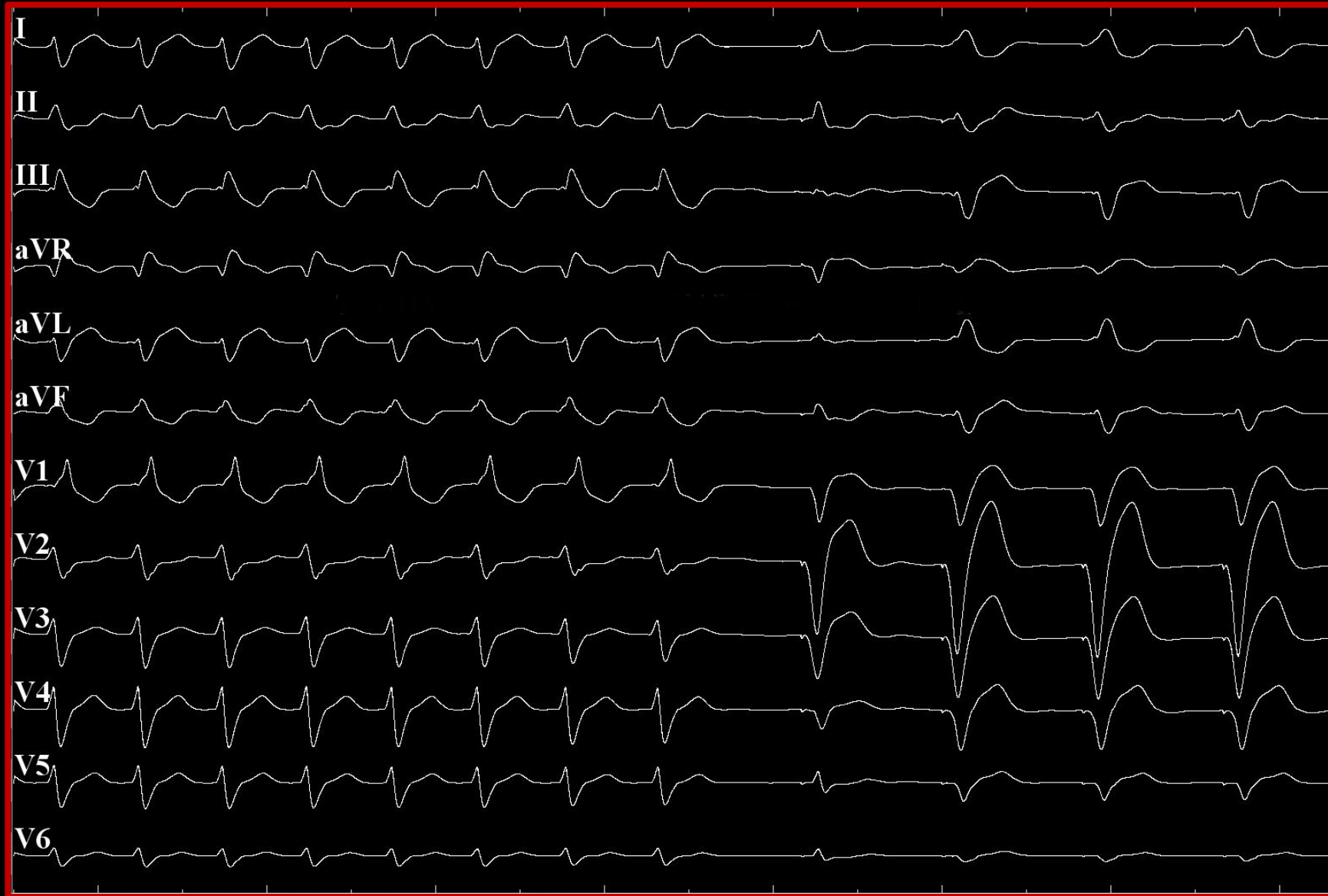AV dissociation

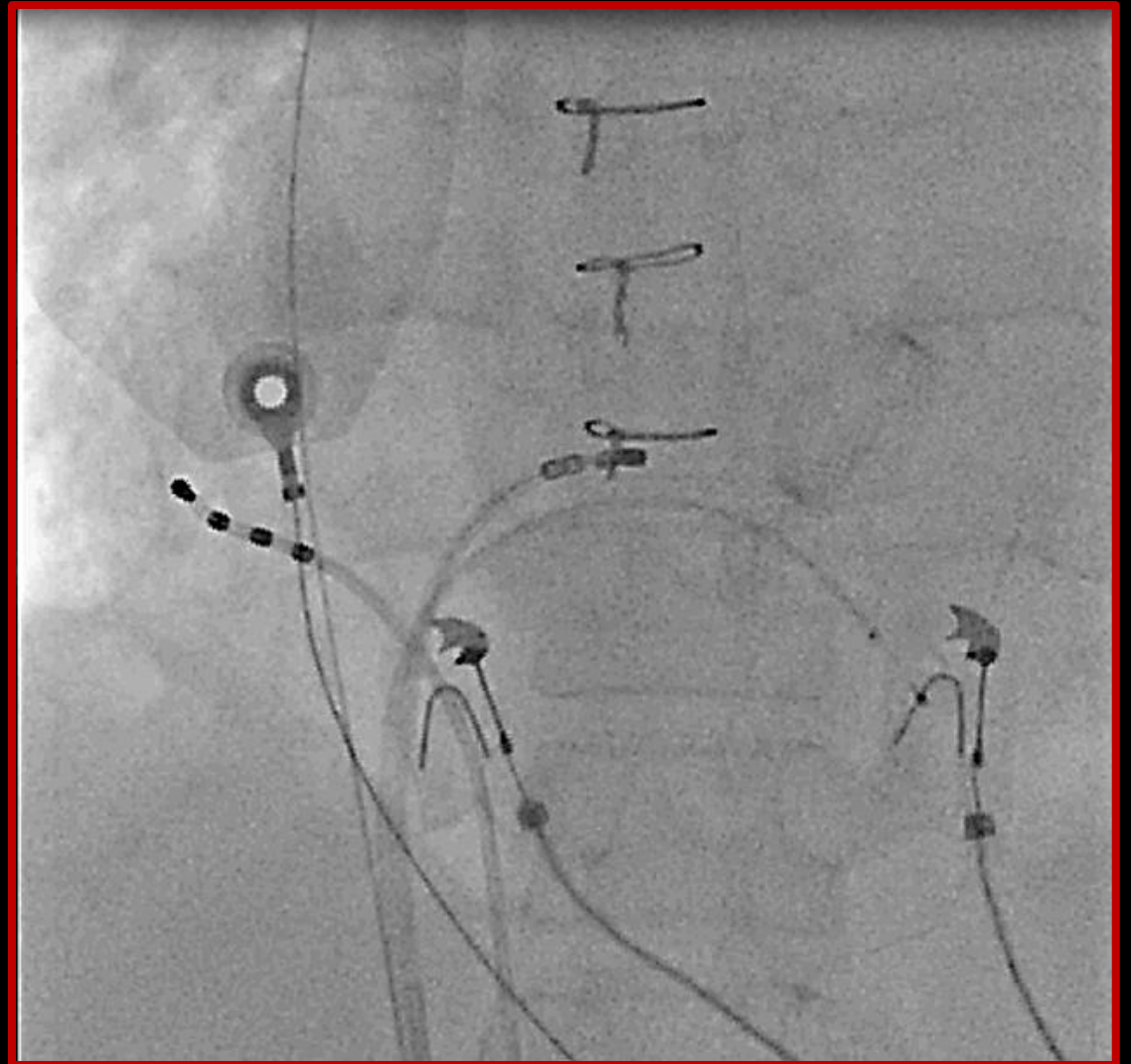
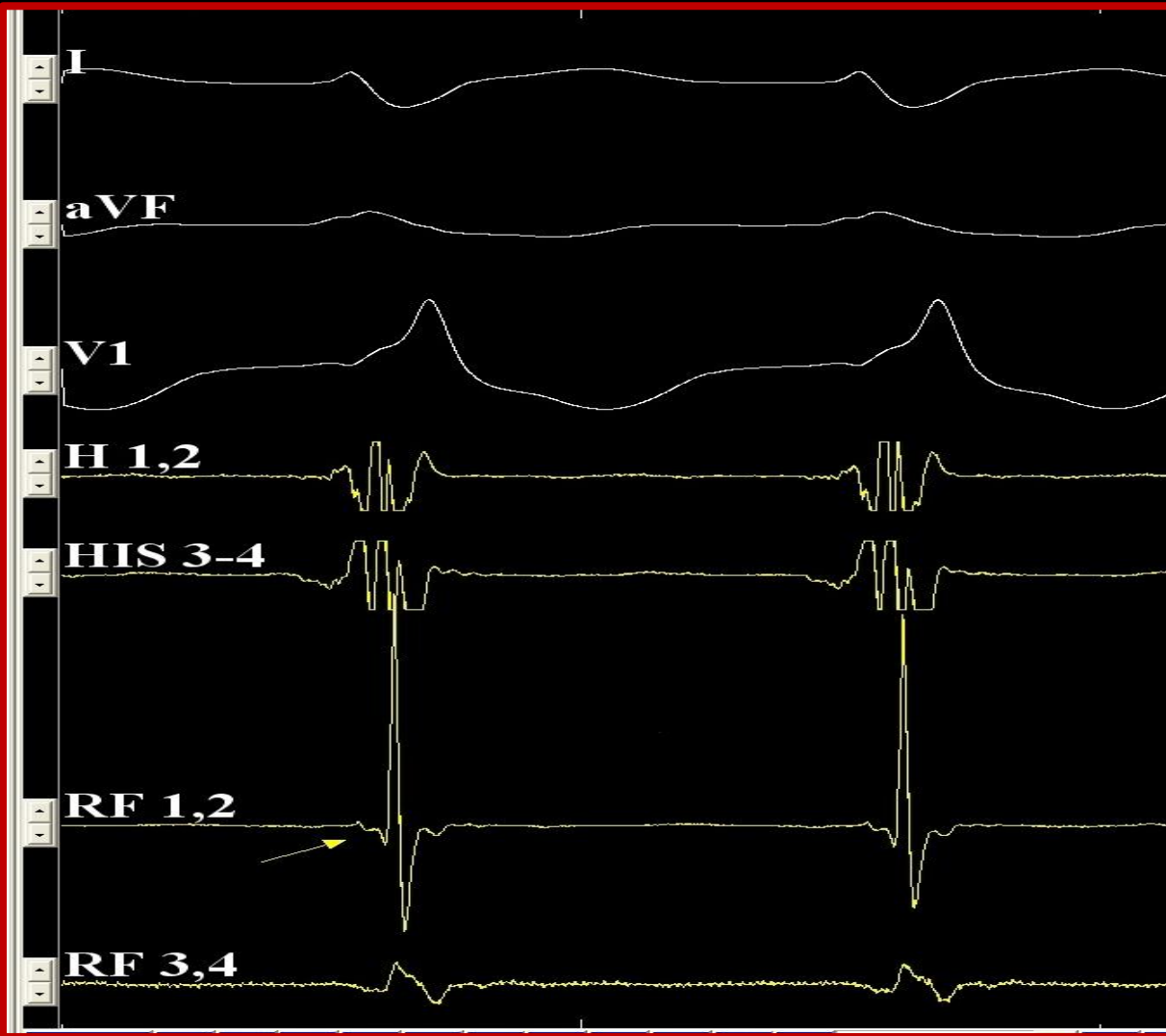


Manifest entrainment from RV with short PPI



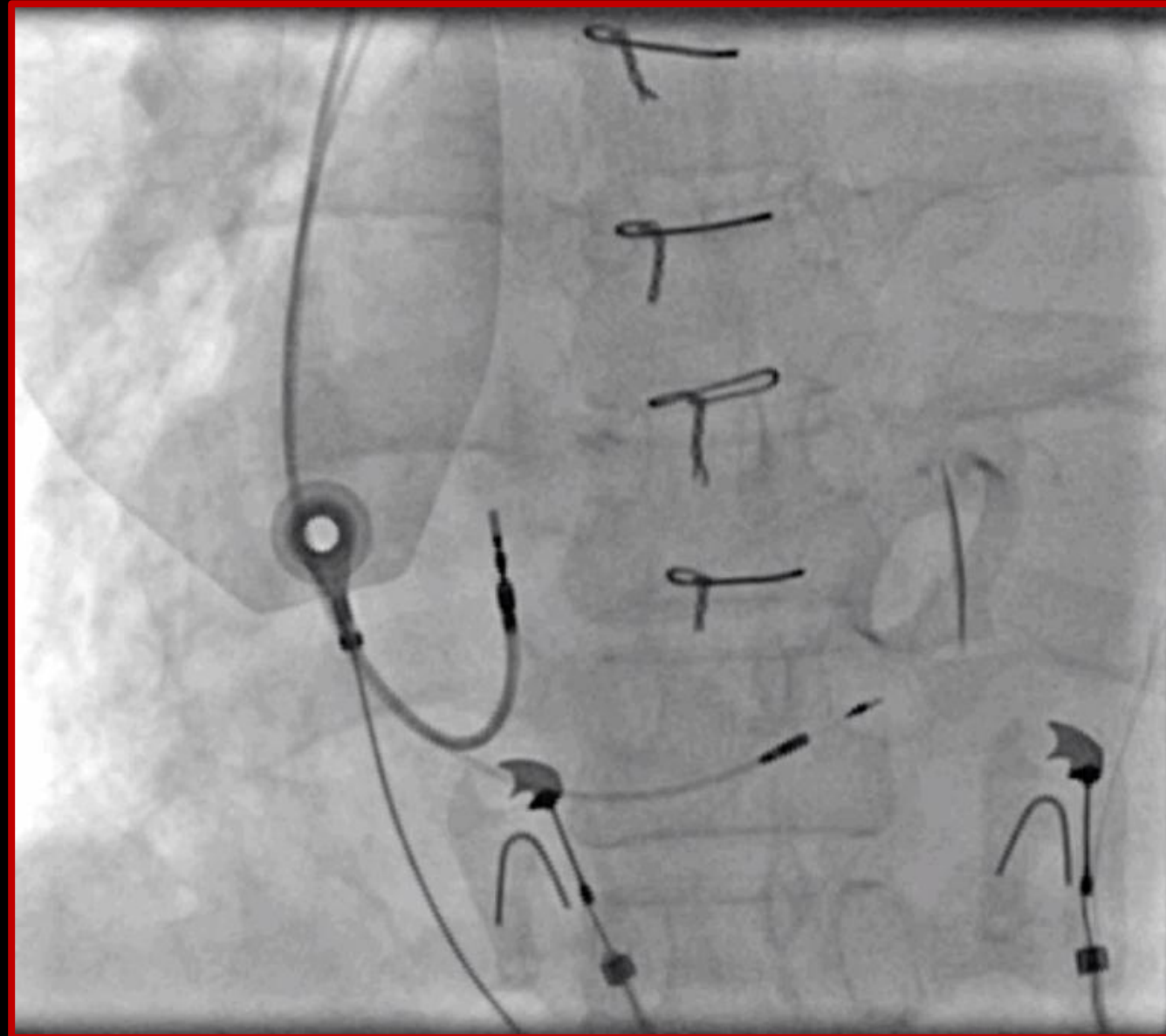
Adenosine terminated the tachycardia



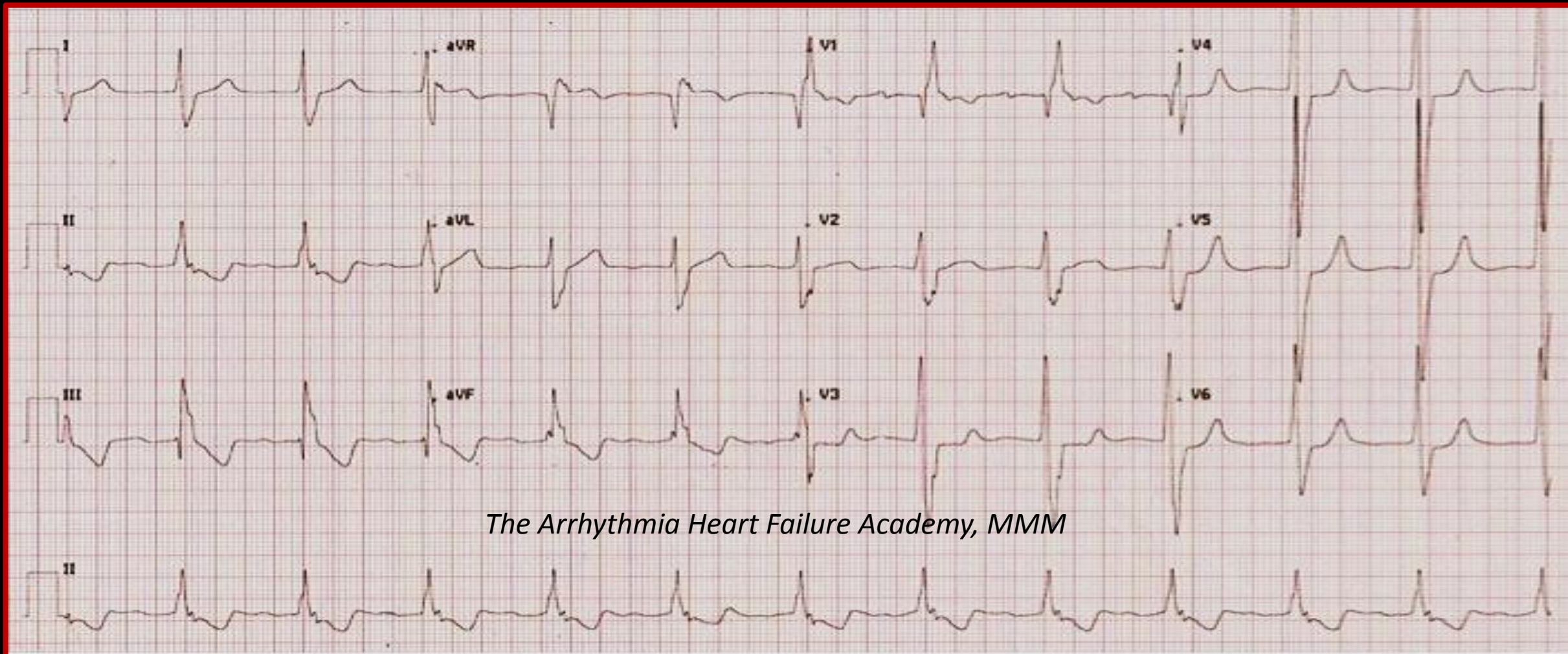


Radiofrequency ablation (40W, 50°C, 7F Therapy™ ablation catheter) at the site where the lead was screwed-in terminated the tachycardia in 5 seconds.

The lead was finally screwed-in distal to the ablation site with satisfactory parameters



During the 1st month follow-up patient remained asymptomatic.
The injury caused by the HBP lead was still evident on the ECG qRBBB and PR interval 240ms.



Take Home Message

During his bundle permanent lead pacing injury to the conduction system is very common- PR prolongation, High grade AV block, CHB, RBBB


Occasionally ectopics can be seen

However incessant ventricular tachycardia which is hemodynamically unstable is so far not reported

Many more lessons to learn from this new technology



THANK YOU



Dr. Kotti MD., DM
Consultant Electrophysiologist
Arrhythmia Heart Failure Academy
The Madras Medical Mission

